

Chapter 2

THE HUMAN BODY: READING THE MAP

LEARNING OBJECTIVES

- ⇒ List and describe the various body positions
- ⇒ Define the body planes and associated directional terms
- ⇒ Locate and describe the body cavities and their respective organs
- ⇒ List and describe the anatomical division of the abdominal region
- ⇒ Identify and locate the various body regions

MULTIMEDIA FOUND ON THE POWERPOINT LECTURE OUTLINE

Videos

1. Body Positions
2. MRIs
3. Radiologic Technology Professional Profile
4. Surgical Technology Professional Profile
5. Ultrasound

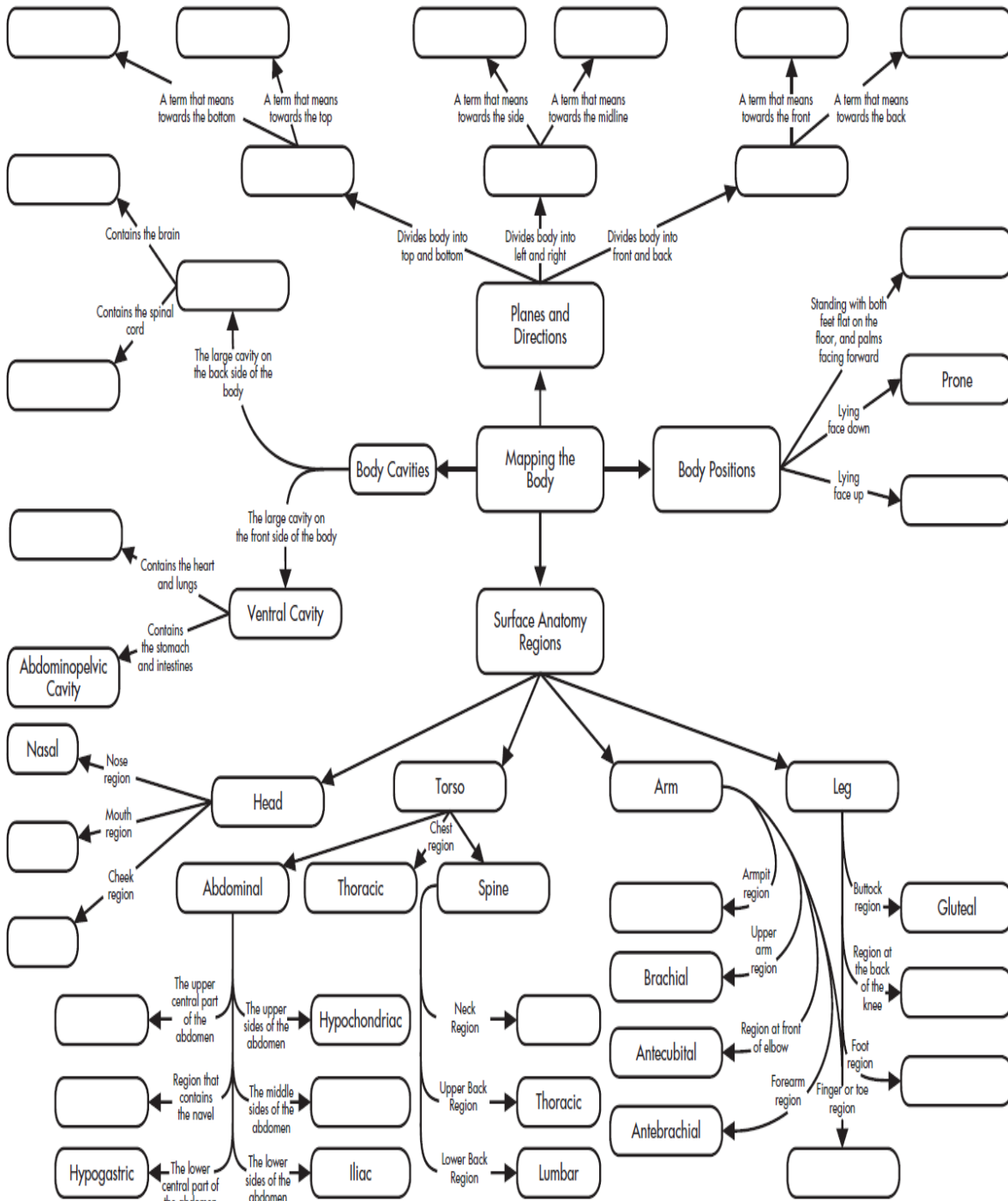
Interactive Labeling Activities

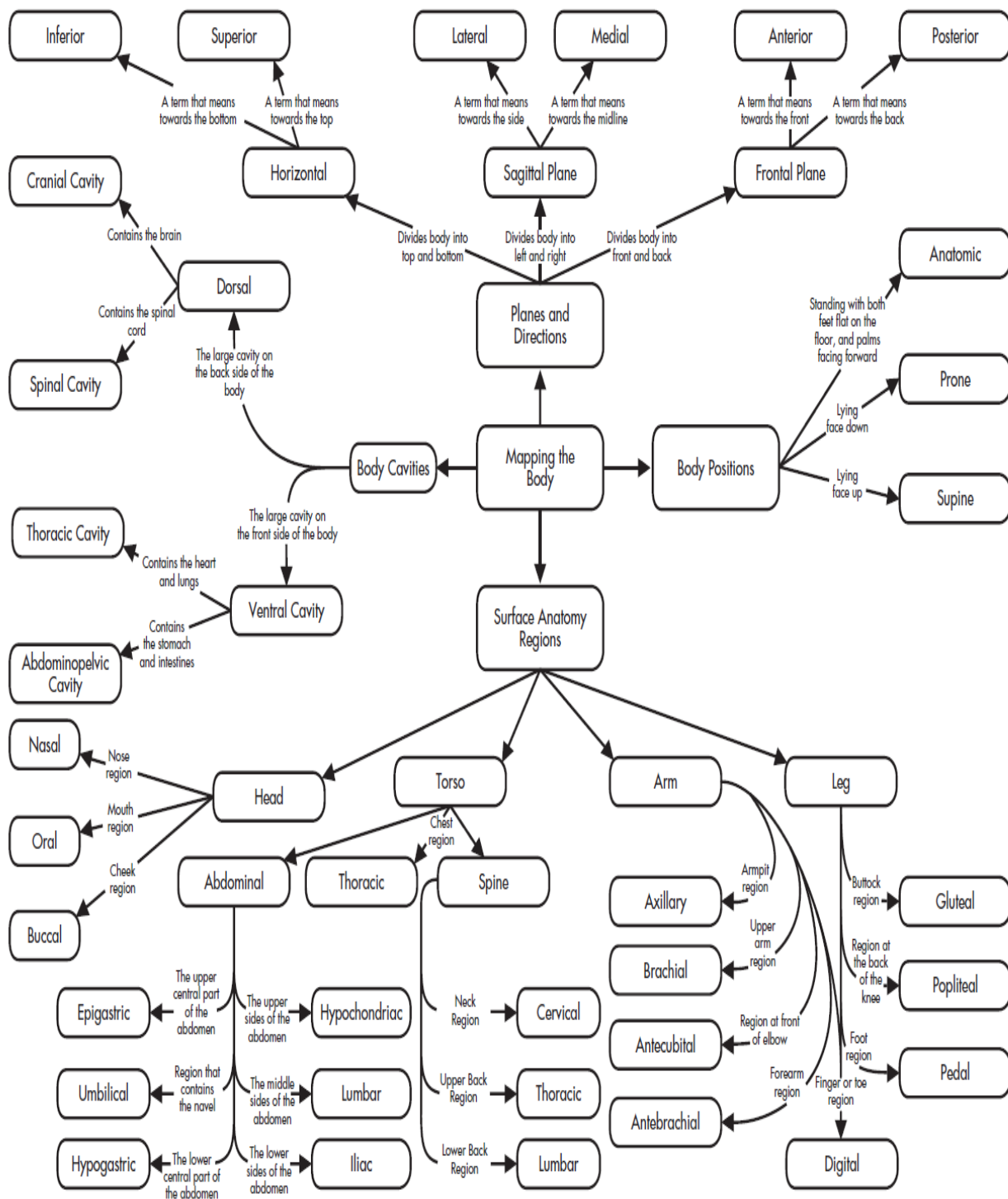
1. Body Cavities
2. Body Positioning

Name _____

INSTRUCTIONS: Fill in the empty boxes with an appropriate term using the clues provided.

CONCEPT MAP





ANSWER KEY

LECTURE OUTLINE

I. Mapping the Human Body

A. Body positions

1. To standardize the orientation for the study of anatomy, the anatomical position was developed: stand erect, face forward, feet apart, arms at side, palms forward
2. Supine: faceup
3. Prone: facedown
4. Trendelenburg: head lower than feet
5. Fowler's: sitting at 45 degrees

II. Directional Terms and Planes of Section

A. Directional terms

1. Depends on comparison to other body parts
2. The point of reference is always from the patient's point of view and is not dependent on which way the patient is facing you
3. Terms usually come in pairs
 - a. Superior (cranial or cephalic): above, toward the head
 - b. Inferior (caudal): below, toward the tail
 - c. Medial: toward the midline
 - d. Lateral: toward the side (away from the midline)
 - e. Anterior (ventral): toward the front, belly
 - f. Posterior (dorsal): back, toward the back
 - g. Proximal: near the origin
 - h. Distal: far from the origin
 - i. Internal: inside the body
 - j. External: near the outside of the body
 - k. Superficial: near the surface
 - l. Deep: far from the surface
 - m. Central: near center of body
 - n. Peripheral: near edges of body

B. Body planes

1. Transverse or horizontal plane: divides body into superior and inferior parts
2. Sagittal plane: divides body into right and left pieces
3. Median or midsagittal plane: divides body into right and left halves
4. Frontal or coronal plane: divides body into anterior and posterior parts

III. Body Cavities

A. House and protect organs

1. Anterior cavity
 - a. Divided by the diaphragm
 - b. Thoracic cavity
 - i. The thoracic cavity is superior to the diaphragm

© 2011 by Pearson Education, Inc

Colbert , Ankney, Lee, *Instructor's Resource Manual for Anatomy and Physiology for Health Professions: An Interactive Journey*, 2nd Edition

- ii. Contains heart, lungs, blood vessels
 - c. Abdominopelvic cavity: inferior to diaphragm.
 - i. Abdominal cavity
 - a. Superior to imaginary line at pelvis
 - b. Contains abdominal organs: stomach, intestines, liver, gallbladder, pancreas, and spleen
 - ii. Pelvic cavity
 - a. Inferior to imaginary line at pelvis
 - b. Contains pelvic organs such as the urinary bladder, reproductive system, rectum, and anus
 - 2. Dorsal cavity
 - a. Cranial cavity houses the brain
 - b. Spinal cavity houses the spinal cord
 - 3. Many smaller cavities throughout the body
- IV. Body Regions
- A. The abdominal region divided into nine quadrants
 - 1. Epigastric is superior to the umbilical region.
 - 2. The right and left hypochondriac is lateral to epigastric.
 - 3. Umbilical region is located in the center, over the umbilicus.
 - 4. Right and left lumbar regions are located on either side of the umbilical region.
 - 5. The hypogastric region lies inferior to the umbilical area.
 - 6. The left and right iliac regions are located on either side of the hypogastric region.
 - B. It is simpler to divide the abdominal region into four quadrants with the center line of the inferior/superior and left/right division being the umbilicus; quadrants are generally abbreviated.
 - 1. Right lower quadrant (RLQ): appendix
 - 2. Right upper quadrant (RUQ): liver, gallbladder
 - 3. Left lower quadrant (LLQ): rectum
 - 4. Left upper quadrant (LUQ): spleen
 - C. Additional body regions: every body part has a technical name

CLASSROOM ACTIVITIES

1. Have students demonstrate various body positions by moving their extremities into the various positions.
2. Play "Go to the Head of the Class." Have all students start in the back of the classroom. Every time they answer a question correctly, they can move one seat forward until eventually they reach the head of the class. Rewards can be extra credit points, food, or privileges.
3. Play "Pin the tail on the anatomy." Have students look for the body part based only on the technical name, or have blindfolded students directed to the point on the "body" by other students using only directional terms.

TEACHING STRATEGIES

1. Give students the names of organs, and ask them to identify in what body cavity the organs would be located.
2. The game “Operation” can be a wonderful teaching tool for body cavities, organs, and anatomical divisions. Play a game where students must answer questions related to the chapter to win a chance to remove one of the “organs” in the game board. Questions should include things like, “What is that organ called in real life?” or “What is the name for the body cavity where that organ is located?” If they successfully remove the organ without making the buzzer go off, they get to draw a card that awards them “money.” At the end of the game, they can use the money they’ve earned to buy rewards like extra credit points.

FACTOIDS

1. Species with a vertebral column are classified as vertebrates and include fish, amphibians, reptiles, birds, and mammals. The various planes apply to veterinary medicine as well, and add the term “*rostral*” to refer to the direction toward the nose. Dorsal and ventral describe the sides closest to the sky and closest to the ground in animals. The terms *anterior* and *posterior* are not necessarily the same as ventral and dorsal in four-legged animals or invertebrates like lobsters.
2. A sagittal plane divides the body into right and left, but does not have to run down the center of the body—it can divide the body at any point. If the plane does run down the center of the body, dividing the body in half, it is a midsagittal plane.
3. Ipsilateral means on the same side, whereas contralateral means on the opposite side.

ETHICAL DILEMMAS

1. Imagine that the doctor told you to surgically prepare the left hypochondriac region of the abdomen for surgery, and you didn’t know where that region was located. Ask students how they would go about finding out where that area was located. Ask them to discuss the ethics of “guessing” the location and potential consequences.
2. What obligation do you have to your patient to understand the information provided in this chapter? What consequences could occur if you fail to meet your obligation?

ANSWERS TO TEST YOUR KNOWLEDGE

Test Your Knowledge 2–1 Answers, p. 26

1. Person should be standing face forward, palms out as in Figure 2-1.
2. Best body position for following circumstances
 - a. Getting a back massage: prone
 - b. Eating in a hospital bed: Fowler's
 - c. Watching television in bed: Fowler's
 - d. Watching the stars at night: supine
3. Give the opposite directional term
 - a. Superior: inferior
 - b. Posterior: anterior
 - c. Caudal: cephalic (cranial)
 - d. Ventral: dorsal
 - e. Distal: proximal
 - f. External: internal
 - g. Superficial: deep
 - h. Peripheral: central
 - i. Medial: lateral
4. superficial
5. proximal; distal
6. superior
7. peripheral or pedal
8. central cyanosis

Test Your Knowledge 2–2 Answers, p. 29

1. transverse or horizontal
2. anterior (ventral); posterior (dorsal)
3. midsagittal
4. Identify the major body cavity in which the following organs are located.
 - a. Heart: thoracic or pericardial
 - b. Spinal cord: spinal, dorsal, or vertebral
 - c. Stomach: abdominal
 - d. Lungs: thoracic or pleural
 - e. Reproductive organs: pelvic
 - f. Brain: cranial
5. nervous

Test Your Knowledge 2–3 Answers, p. 35

1. oral
2. axillary
3. umbilical
4. lumbar
5. patellar
6. spleen or liver

ANSWERS TO CASE STUDY, P. 36

- a. right knee
- b. center of the chest (breastbone area)
- c. left arm
- d. no stomach pain
- e. in front of elbow
- f. feet

ANSWERS TO REVIEW QUESTIONS, P. 37

Multiple Choice

1. a, 2. d, 3. d, 4. d, 5. a, 6. d

Fill in the Blank

- 1. anatomical
- 2. supine
- 3. inferior; superior
- 4. brain
- 5. peripheral or acrocyanosis
- 6. midsagittal

Short Answers

- 1. The organs found in the abdominal cavity are the liver, stomach, pancreas, spleen, gallbladder, small intestine, and part of the large intestine.
- 2. In the prone position a person is lying facedown. In the supine position a person is lying faceup. In Fowler's position, a person is sitting up at a 45 to 60 degree angle.
- 3. There are three superior regions in the abdominal cavity. The medial superior region is the epigastric (above the stomach) region. The lateral superior regions are the hypochondriac (under the ribs) regions. Inferior to those three regions are two lateral regions, the lumbar regions, and a medial region, the umbilical region. The three most inferior regions are two lateral regions, the iliac regions and one medial region, the hypogastric (under the stomach) region.

Name _____

CHAPTER 2 – WORKSHEET

Multiple Choice

- 1) In this position, a patient is lying on their back, faceup.
 - A) Prone
 - B) Supine
 - C) Trendelenburg
 - D) Fowler's
- 2) In this position, a patient is lying on their stomach, facedown.
 - A) Anatomical
 - B) Trendelenburg
 - C) Prone
 - D) Supine
- 3) In this position, a patient is lying with the head of the bed lower than the feet.
 - A) Trendelenburg
 - B) Prone
 - C) Fowler's
 - D) Anatomical
- 4) A patient is standing erect, with face forward, feet parallel, arms hanging to the side, and palms facing forward. What position is this patient in?
 - A) Supine
 - B) Anatomical
 - C) Fowler's
 - D) Prone
- 5) A patient has a slightly blue discoloration to the fingers and toes. This is an example of _____ cyanosis.
 - A) central
 - B) peripheral
 - C) lateral
 - D) sagittal

Fill in the Blank

- 6) _____ The plane divides the body into left and right portions.
- 7) The _____ plane divides the body into anterior and posterior parts.
- 8) Another name for the midsagittal plane is the _____ plane.
- 9) The _____ plane divides the body into superior and inferior parts.
- 10) The cranial and spinal cavities are both part of the larger _____ cavity.
- 11) The thoracic and abdominal cavities are part of the larger _____ cavity.

Worksheet – p. 1 of 2

Matching

Please match the following terms with the correct definition.

- | | | |
|-----------|-------------|--|
| 12) _____ | Sternal | A. Foot region |
| 13) _____ | Pedal | B. Neck region |
| 14) _____ | Pubic | C. Cheek region |
| 15) _____ | Axillary | D. Breastbone region |
| 16) _____ | Cervical | E. Finger region |
| 17) _____ | Epigastric | F. Chest region |
| 18) _____ | Thoracic | G. Nose region |
| 19) _____ | Gluteal | H. Genital region |
| 20) _____ | Lumbar | I. Buttock region |
| 21) _____ | Oral | J. Superior central portion of the abdomen |
| 22) _____ | Buccal | K. Front of the elbow |
| 23) _____ | Antecubital | L. Low back region |
| 24) _____ | Digital | M. Mouth region |
| 25) _____ | Nasal | N. Armpit region |

Short Answer/Essay

26. List three organs that might be found in the abdominal cavity.

27. Give one example of an organ found in the thoracic cavity.

ANSWER KEY

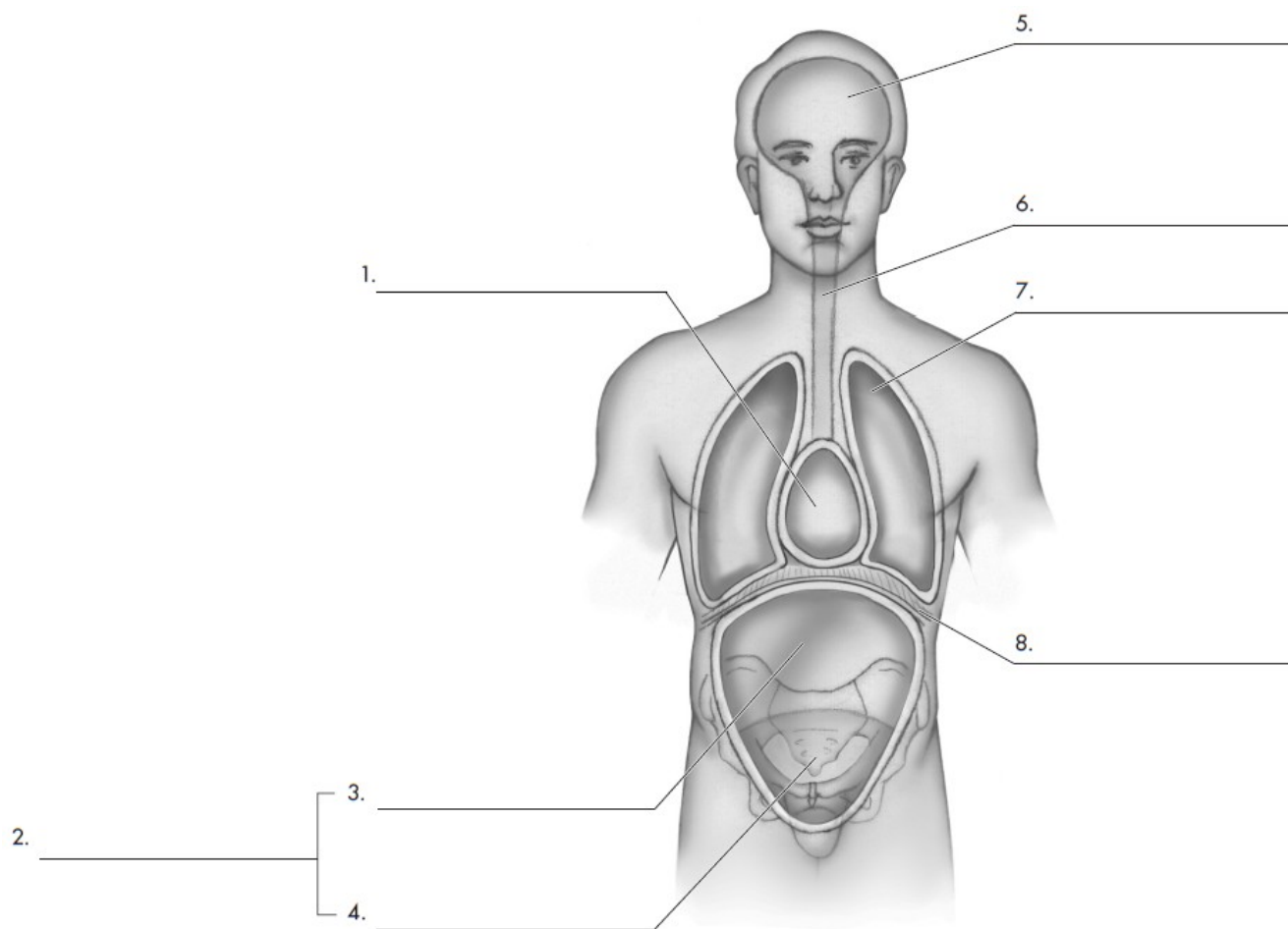
Chapter 2—Worksheet

- 1) B
- 2) C
- 3) A
- 4) B
- 5) B
- 6) sagittal
- 7) frontal/coronal
- 8) median
- 9) horizontal/transverse
- 10) dorsal
- 11) ventral
- 12) D
- 13) A
- 14) H
- 15) N
- 16) B
- 17) J
- 18) F
- 19) I
- 20) L
- 21) M
- 22) C
- 23) K
- 24) E
- 25) G
- 26) Answers will vary, but may include stomach, intestines, liver, kidneys, bladder, etc.
- 27) Answers will vary, but may include heart, lungs, esophagus, etc.

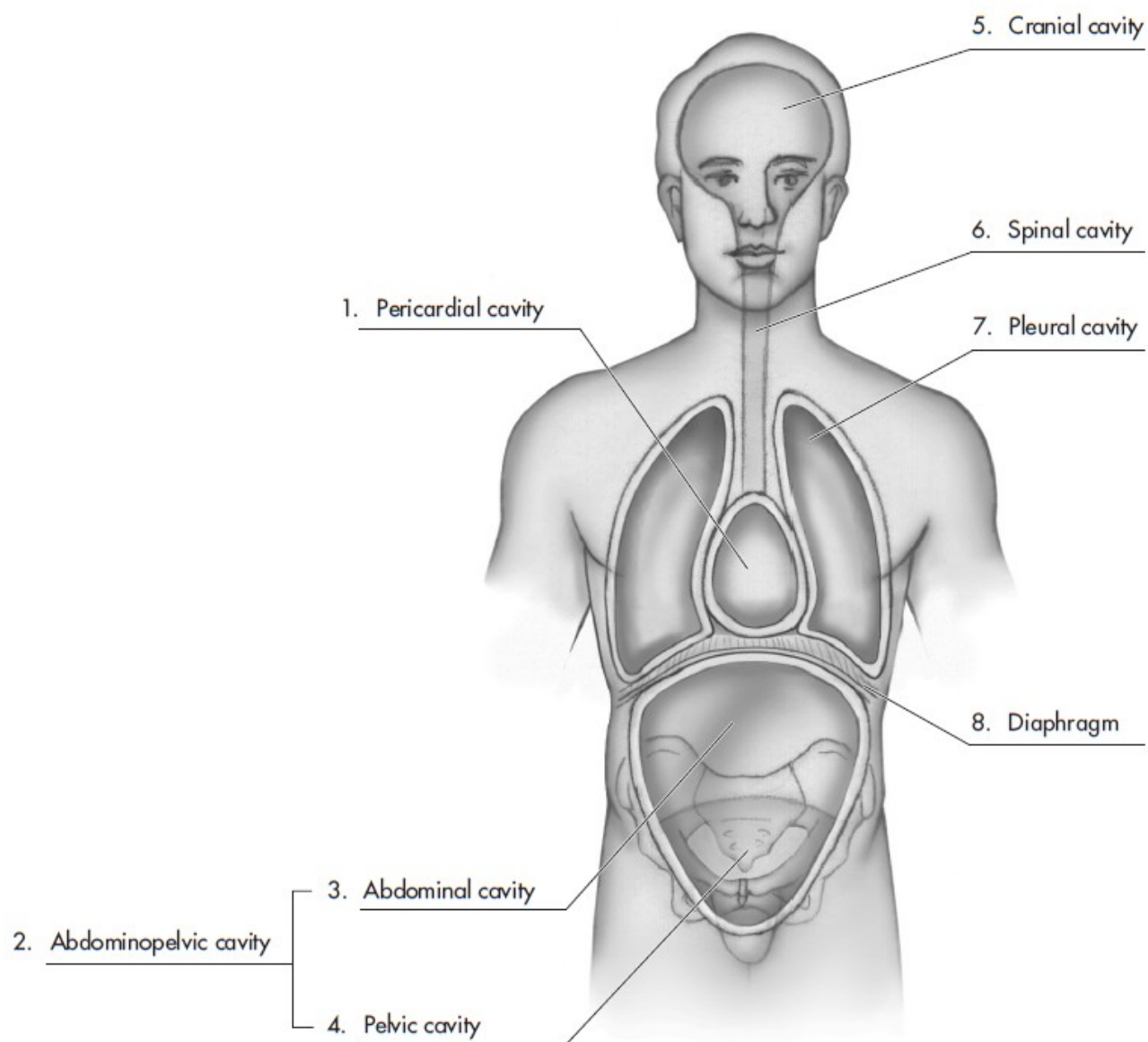
Name _____

LABELING ACTIVITY #1

INSTRUCTIONS: Please label the cavities in the following diagram.



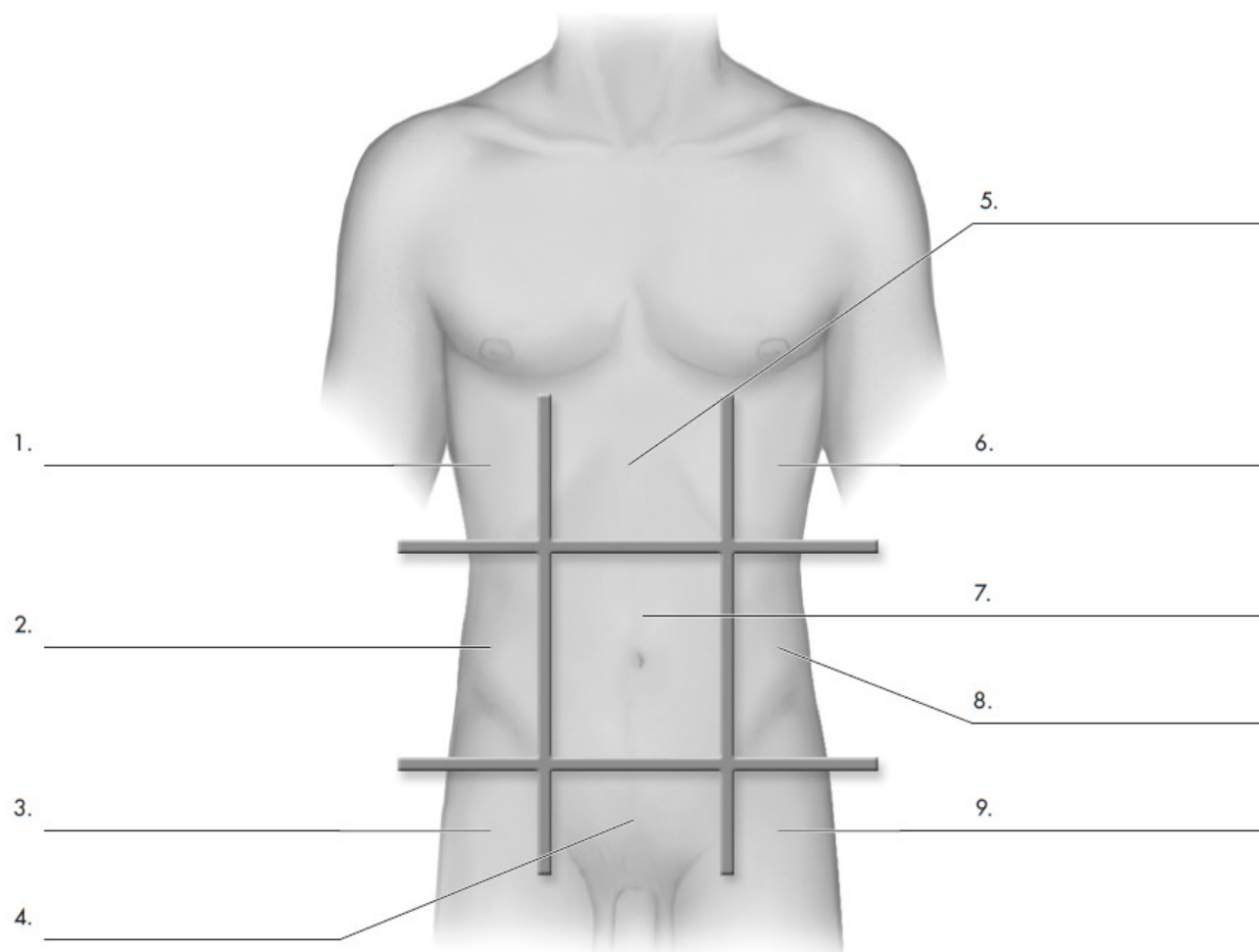
LABELING ACTIVITY #1 ANSWER KEY



Name _____

LABELING ACTIVITY #2

INSTRUCTIONS: Please label the following regions.



© 2011 by Pearson Education, Inc

Colbert , Ankney, Lee, *Instructor's Resource Manual for Anatomy and Physiology for Health Professions: An Interactive Journey*, 2nd Edition

LABELING ACTIVITY #2 ANSWER KEY

